

lights=off&pa=5Ba77ba1b3%2d150WUHF4u6f9pXc3gZ5X%KEg9IH059P moat1QoM/YguqD84%2d1pt.sQ2o%2d8H7bVmdscd8p8baToWwIF50P4ZRoq21%3d Search...

ACC:3037588 DOB:18-Jun-1982 Age:38y Date:23-Sep-2020 10:44 XR RADIUS & ULNA, AP & LAT, LEFT Location:Unspecified



Primary
KHOO TECK PUAT HOSPITAL
Study Date: 23-Sep-2020
Study Time: 10:44:25



AMURTHY, . Age: 38y Sex: M
NA, AP & LAT, LEFT
AP LEFT

Global Stack
ARUNKUMAR RAMAMURTHY, . Age: 38y Sex: M
Patient ID: 98260203H
ACC: 3037588
DOB: 18-Jun-1982
XR RADIUS & ULNA, AP & LAT, LEFT
RADIUS & ULNA LAT LEFT
Sb: 2
Im: 1/1

COPIED Print
KHOO TECK PUAT HOSP
Study Date: 23-Sep-20
Study Time: 10:44



Q 9.20
10.18.11 10.2.3602

Q 0.22
11.02.AM 23.9.2020



Primary
KHOO TECK PIAT HOSPITAL
Study Date: 20-06-2020
Study Time: 12:22:24

Global Stock
ARUNACHAL PRADESH, INDIA
Patient ID: 5128020304
ACC: 2108503
DOB: 15-Jun-1982

XR RADIUS & ULNA, AP & LAT, LEFT
RADIUS & ULNA, LAT, LEFT
Ser 2
Ser 3

20 Minv ☒ CPACS
XR RADIUS & ULNA, AP & LAT, LEFT
23 Sep ☒ CPACS
XR RADIUS & ULNA, AP & LAT, LEFT

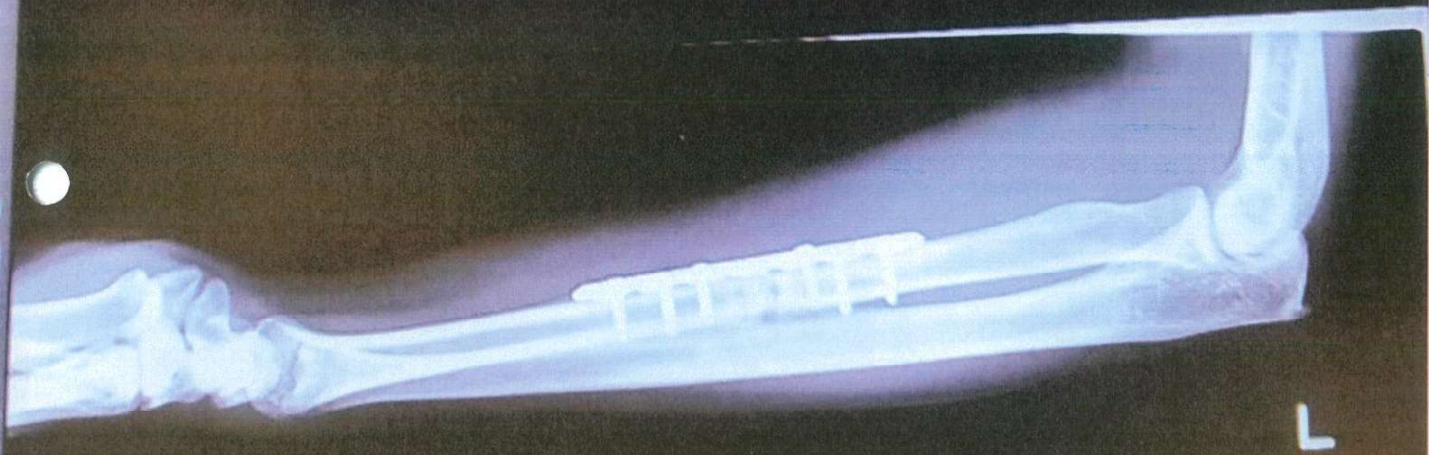
21 Aug ☒ CPACS
XR RADIUS & ULNA, AP & LAT, LEFT
06 Aug ☒ CPACS
XR RADIUS & ULNA, AP & LAT, LEFT

08 Aug ☒ CPACS
OT FLUOROSCOPY 1ST 3
28 Jul ☒ CPACS
XR RADIUS & ULNA, AP & LAT, LEFT

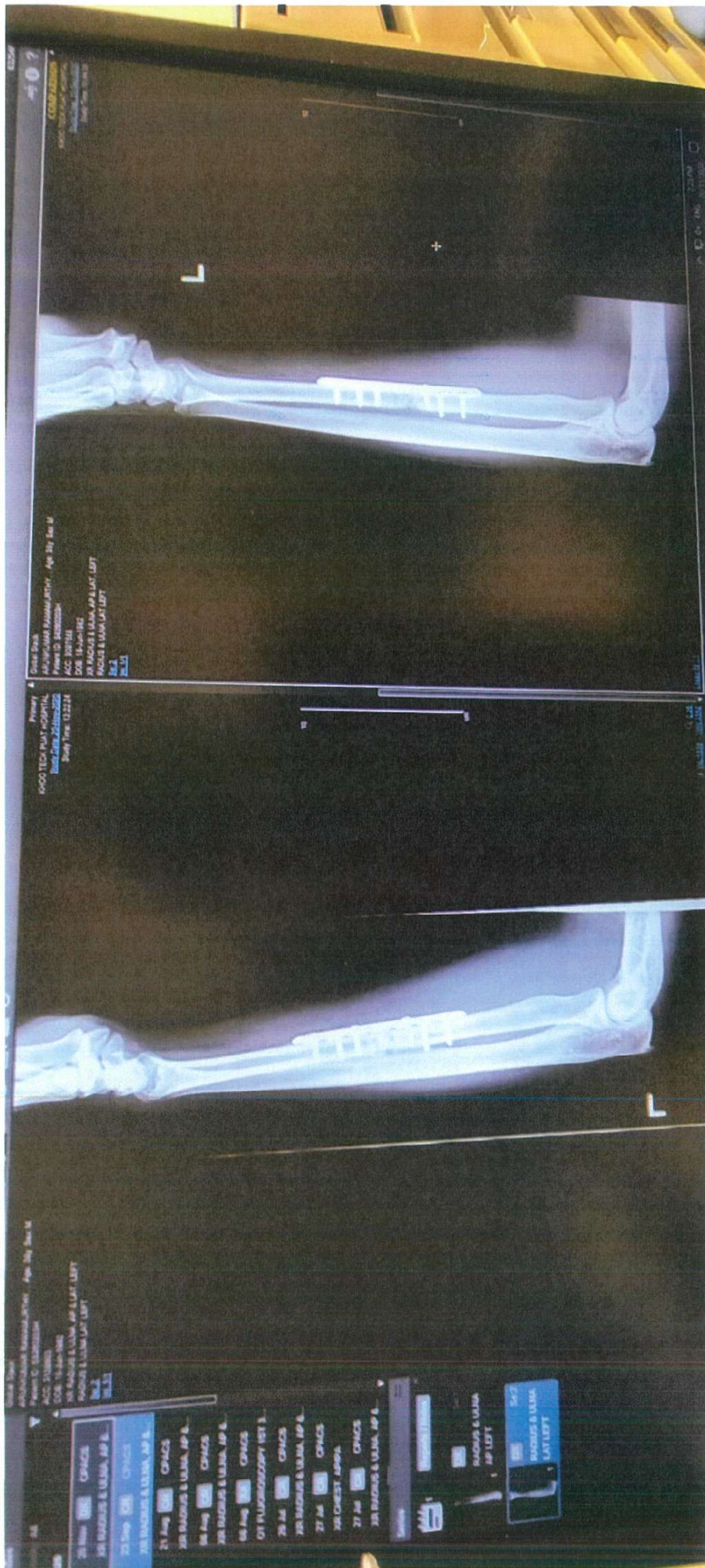27 Jul ☒ CPACS
XR CHEST, AP/PA
27 Jul ☒ CPACS
XR RADIUS & ULNA, AP & LAT, LEFT

Series
R: RADIUS & ULNA, AP & LAT, LEFT
S: RADIUS & ULNA, LAT, LEFT

Ser 2
R: RADIUS & ULNA, AP & LAT, LEFT
S: RADIUS & ULNA, LAT, LEFT



Q. 0.2
W. 0.18
H. 0.18



2?mode=inbound&lights=off#p=D26fkmEnhd2MotuASf9kvvuo99Lfm5xEPtKtCd%2F%2b3W8981pOIHq5W3%2b3mmODR%2B3Ac6f4q - Search...

171 ID: S8260203H ACC: 3184501 DOB: 18-Jun-1982 Age: 38y Date: 30-Dec-2020 15:48 XR RADIUS & ULNA, AP & LAT, LEFT Location: Unspecified

Global Stack

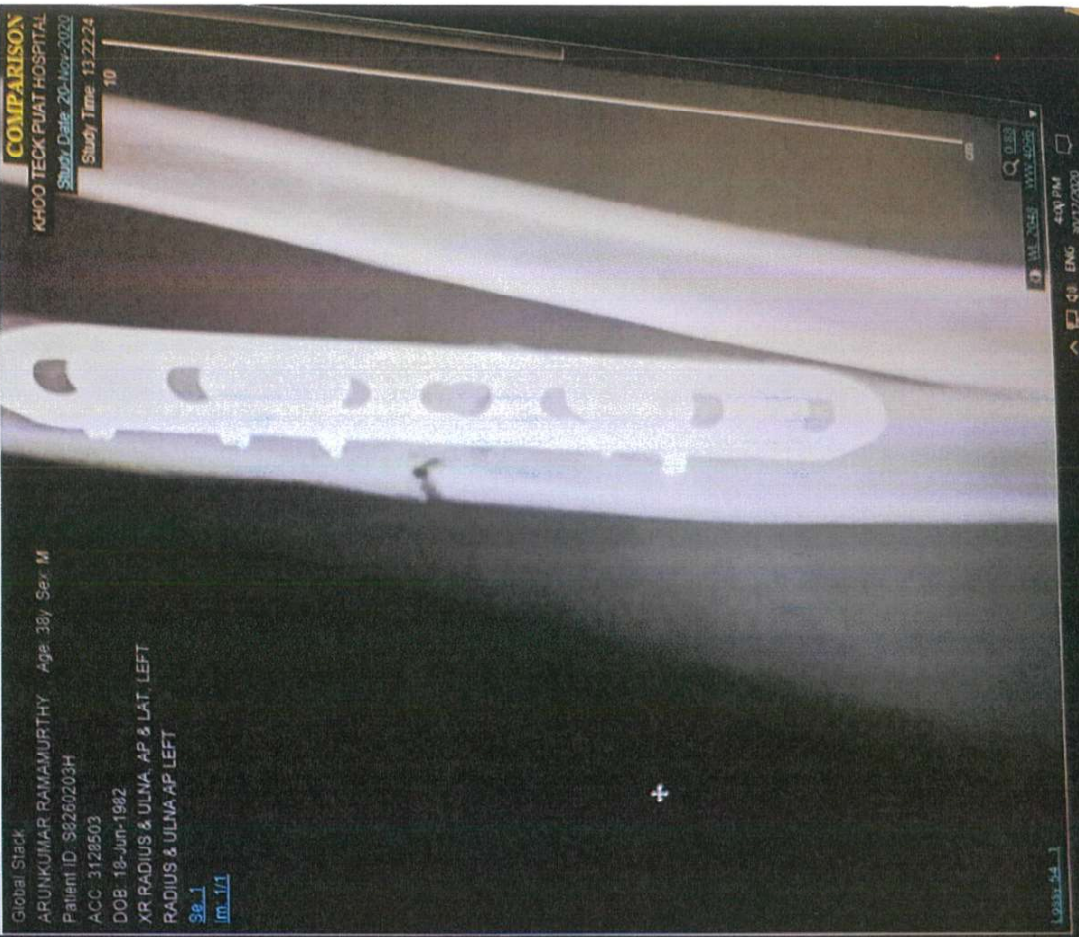
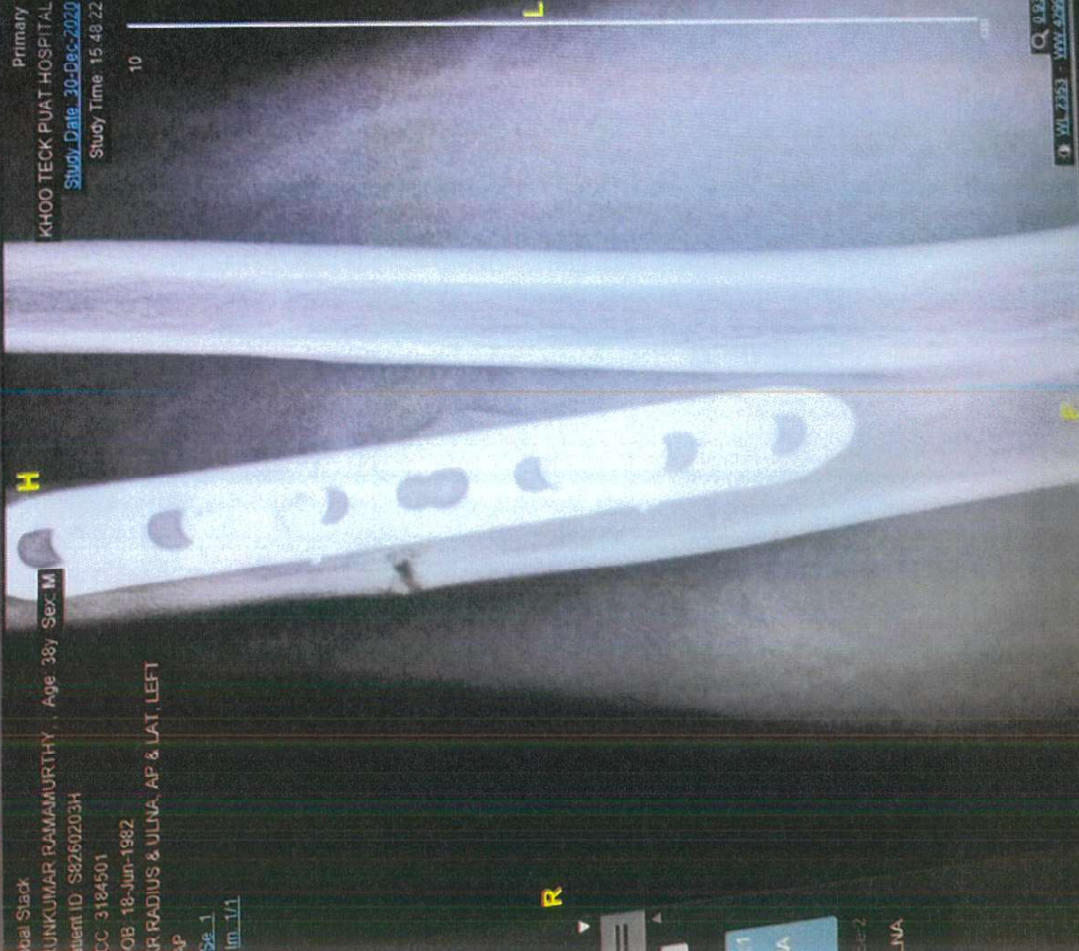Primary

Search

10

Global Stack
APUNKUMAR RAMAMURTHY, Age 38y Sex M
Patient ID: S8260203H
ACC: 3184501
DOB: 18-Jun-1982
XR RADIUS & ULNA, AP & LAT, LEFT
Se 1 Im 1/1

Global Stack
APUNKUMAR RAMAMURTHY, Age 38y Sex M
Patient ID: S8260203H
ACC: 3128503
DOB: 18-Jun-1982
XR RADIUS & ULNA, AP & LAT, LEFT
RADIUS & ULNA AP LEFT
Se 1 Im 1/1



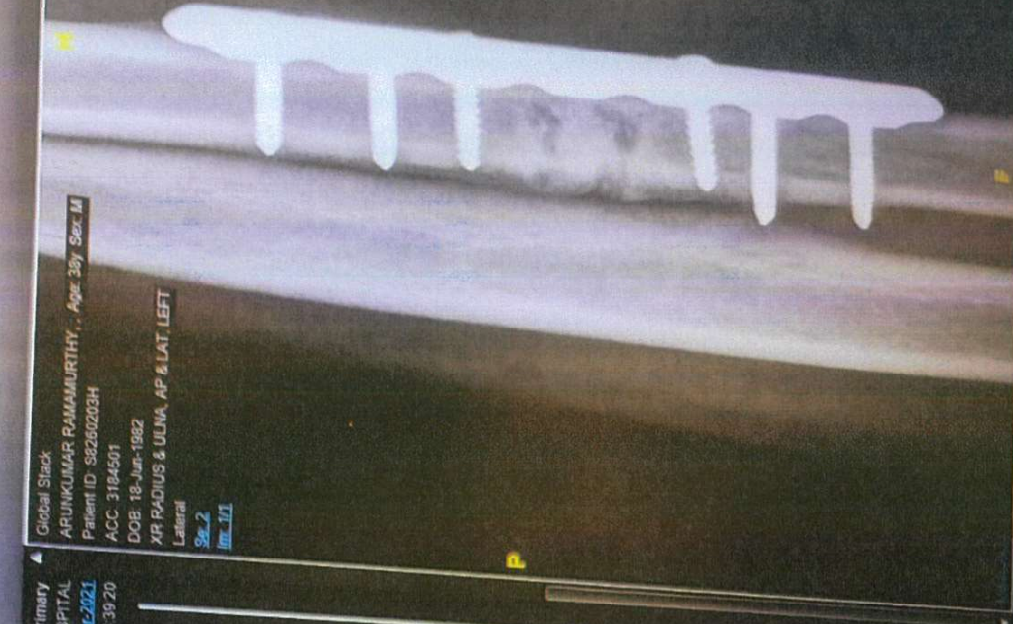
Pathology.com.sg ZIPP/modes/inbound/brightside/127CQVteTvleazZchodieg~2RfaMmt/Dqy5%272z4PqXQa8DJB4HCH9VWV565MqJL6IPDxmI5Z%3chWpPfa439Kc4uDMa4PR1H4aOP9n3 - Search

Primary KHOO TECK PUAT HOSPITAL
Study Date: 26-Mar-2021
Study Time: 14:39:20

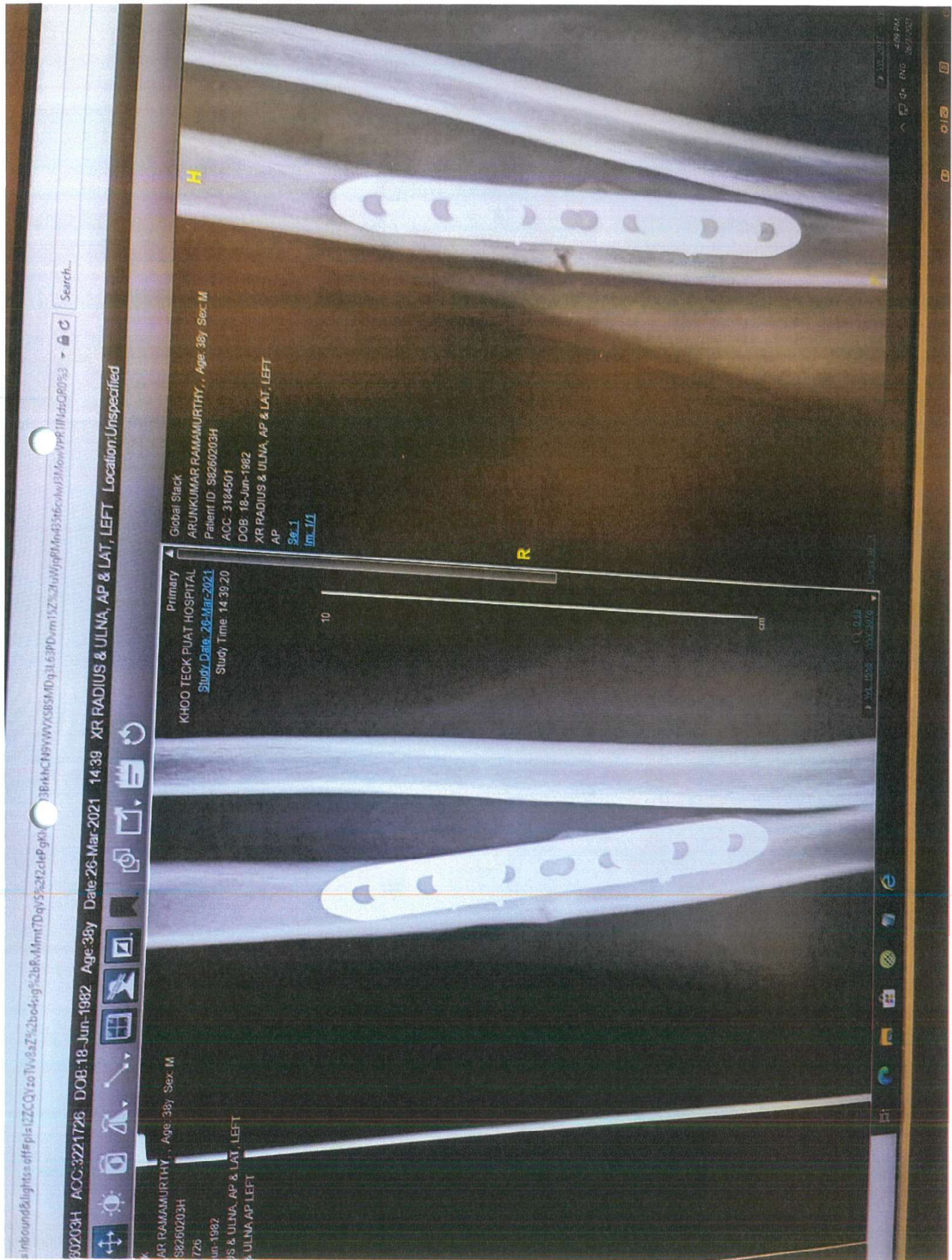Global Stack
ARUNKUMAR RAMAMURTHY, . Age: 38y Sex: M
Patient ID: S8260203H
ACC: 3221726
DOB: 18-Jun-1982
XR RADIUS & ULNA, AP & LAT, LEFT
RADIUS & ULNA LAT LEFT

ACS
A, AP & ...
PACS
NA, AP & ...
CPACS
LNA, AP & ...
CPACS
ULNA, AP & ...
CPACS
ULNA, AP & ...

Global Stack
ARUNKUMAR RAMAMURTHY, . Age: 38y Sex: M
Patient ID: S8260203H
ACC: 3184501
DOB: 18-Jun-1982
XR RADIUS & ULNA, AP & LAT, LEFT
Lateral
Sec 2
Im 1/1



Type here to search



Search...

Location: Unspecified

Global Stack
ARUNKUMAR RAMAMURTHY, Age: 38y, Sex: M
Patient ID: S8260203H
ACC: 31824501
DOB: 18-Jun-1982
XR RADIUS & ULNA, AP & LAT, LEFT
AP
S8.1
Im_1/1

Primary
KHOO TECK PUAT HOSPITAL
Study Date: 26-Mar-2021
Study Time: 14:39:20

AR RAMAMURTHY, Age: 38y, Sex: M
S8260203H
18-Jun-1982
RADIUS & ULNA, AP & LAT, LEFT
& ULNA AP LEFT

CONFIDENTIAL

Your Ref : RA.516307.D
Our Ref : 2020-5610-0

31st August 2020

**RIAZ L.L.C
133 NEW BRIDGE ROAD
#09-09
CHINATOWN POINT
SINGAPORE 059413**

Dear Sirs,

Through: Head, Acute and Emergency Care Centre, Khoo Teck Puat Hospital,

**NAME : ARUNKUMAR RAMAMURTHY
NRIC NO : S8260203H**

The above mentioned patient was seen on 26th July 2020 at the Acute and Emergency Care Centre of Khoo Teck Puat Hospital. He was attended to by Dr Yi Wen Mathew Yeo, Dr Xue Bi May Na, Dr Michael Liu and Dr Kailing Adriel Rao.

Patient was involved in a road traffic accident on the same day. He was a motorcyclist and had collided with a taxi. He claimed to have flung onto the taxi's boot and possibly had lost consciousness. He was unable to recall the events of the accident. He was complaining of pain over his neck and left forearm.

On examination, he was alert. There was no head injury wound noted and no cervical spine tenderness on palpation. He was tender over the right paraspinal region. There was a superficial laceration wound noted over his inner lower lip. He had good air entry into his lungs with normal heart sounds on auscultation. His abdomen was soft and non-tender on palpation. His left forearm was swollen with an overlying superficial abrasion wound. Point of care ultrasound examination did not show any free intra-abdominal fluid.

XRays of his chest, pelvis, left elbow, left radius and ulna, and left wrist showed possible right lung contusion changes and displaced comminuted fracture of the left radius mid-shaft. A CT scan of his brain and cervical spine did not show any acute pathology. He was reviewed by the General and Orthopaedic Surgeons. Patient had declined an operation for his left arm. His left upper limb was placed into a backslab. He was treated with analgesia, antibiotic and a dose of anti-tetanus toxoid vaccine. He was admitted to the EDTU ward.

A repeat XRay of his chest the next morning confirmed that there was no lung contusion changes. He was eventually discharged on the 27th July 2020 with advice, drug prescription and 4 days of hospitalization leave certification. He was also referred to the Orthopaedics Fracture clinic to be reviewed as an outpatient.

Impression: Left Galeazzi fracture and neck strain secondary road traffic accident.

CONFIDENTIAL

Khoo Teck Puat Hospital
90 Yishun Central
Singapore 768828
Tel: (65) 6555 8000
Fax: (65) 6602 3700
Reg. No.: 200717564H
www.ktph.com.sg

Your Ref : RA.516307.D
Our Ref : 2020-5610-0



DR FRANCESCA THNG
RESIDENT PHYSICIAN
ACUTE AND EMERGENCY CARE CENTRE
KHOO TECK PUAT HOSPITAL
MCR: M65014E



Dr Toh Hong Chuen
MBBS (Singapore), MRCSEd (A&E), FAMS, MHPE
Senior Consultant, Acting HOD
Acute & Emergency Care Centre
Khoo Teck Puat Hospital
MCR No. M09413G

The above findings are with reference to clinical notes done by Dr Yi Wen Mathew Yeo, Dr Xue Bi May Na, Dr Michael Liu and Dr Kailing Adriel Rao.

Your Ref : RA.516307.D
Our Ref : MR22 2020-5610-0
Date : 26 Aug 2020

RIAZ L.L.C
133 NEW BRIDGE ROAD
#09-09
CHINATOWN POINT
SINGAPORE 059413

ATTENTION:

RE: MEDICAL REPORT FOR ARUNKUMAR RAMAMURTHY (NRIC NO: S8260203H)

We refer to your request dated 25 Aug 2020 for a medical report. The medical report will be forwarded in due course.

For patients who are collecting the report personally, please bring along your NRIC. If patient is authorising someone to collect on his/her behalf, please provide a photocopy of patient's NRIC and an authorisation letter. Please note that Ministry of Manpower Workmen Compensation Report will be forwarded directly to the Ministry.

Thank you.

Health Information Services(MRO)
Khoo Teck Puat Hospital

OFFICIAL RECEIPT

GST REG NO.: 200717564-H

Receipt No. : MRS-76239

Date : 26 Aug 2020

ORIGINAL

SERVICE DESCRIPTION	AMOUNT (\$\$)
ORDINARY MEDICAL REPORT	90.00
ARUNKUMAR RAMAMURTHY S8260203H	
Your Ref : RA.516307.D	
Our Ref : MR22 2020-5610-0	
Payment : CHEQUE DBS 004395	

7% GST is included in the amount charged.

Note: Administrative charges of 1/3 of the cost of medical report will be imposed if a cancellation request is made while the medical report is being processed.

For enquiries, please contact Elena Low See Chun
Tel No: 6602 2477/6602 2477/ Khoo Teck Puat Hospital

Your Ref : RA.516307.D
Our Ref : 2020-5639-0

26 AUGUST 2021

RIAZ L.L.C
133 NEW BRIDGE ROAD
#09-09 CHINATOWN POINT
SINGAPORE 059413

Dear Sir/Madam,

SPECIALIST MEDICAL REPORT FOR ARUNKUMAR RAMAMURTHY
S8260203H

The above mentioned patient first seen in our Specialist Outpatient Clinic (SOC) on 29/07/2020 as a referral from the Emergency Department. He was involved in a road traffic accident on 26/07/2020. Clinical examination revealed a deformity over the left forearm. There were no open wounds. There were no neurovascular deficits in his left upper limb. XRays showed a displaced left radial shaft fracture. In view of his injury, the patient was counselled for surgery with the risks versus benefits discussed extensively.

The patient underwent surgical fixation of his left radial shaft on 6/8/2020. The surgery was uneventful and he was discharged on 8/8/2020.

He was subsequently reviewed in the SOC. His surgical wound healed well and serial XRays showed progressive healing of the fracture. His range of motion of his elbow, in particular, pronation and supination was satisfactory. The XRays performed on 23/7/21 showed complete healing of his fracture.

During the last review in the SOC on 11/8/21, the patient claimed he was well. He had resumed his work 4 months after the accident. He claimed that he has no problems in the course of his work. He has resumed sporting activities, notably weights training in the gym approximately 3 times a week. He does not have issues with his activities of daily living, and is back to riding his motorcycle. Clinical examination showed:

Left elbow range of motion:
Flexion-extension arc 0 to 150 degrees
Pronation 0 to 80 degrees
Supination 0 to 75 degrees

**SPECIALIST MEDICAL REPORT FOR ARUNKUMAR RAMAMURTHY
S8260203H**

Based on the "A guide to the assessment of traumatic injuries and occupational diseases for workmen's compensation" 5th edition, the patient has a score of 0.5% in terms of incapacity. He is unlikely to require future surgeries.

Yours sincerely,



Dr Ng Shao Hui Allan
Consultant
Department of Orthopaedic Surgery

Your Ref : RA.516307.D
Our Ref : SR09 2020-5639-0
Date : 28 Aug 2021

RIAZ L.L.C
133 NEW BRIDGE ROAD
#09-09
CHINATOWN POINT
SINGAPORE 059413

ATTENTION:

RE: MEDICAL REPORT FOR ARUNKUMAR RAMAMURTHY (NRIC NO: S8260203H)

We refer to your request dated 25 Aug 2020 for a medical report. The medical report will be forwarded in due course.

For patients who are collecting the report personally, please bring along your NRIC. If patient is authorising someone to collect on his/her behalf, please provide a photocopy of patient's NRIC and an authorisation letter. Please note that Ministry of Manpower Workmen Compensation Report will be forwarded directly to the Ministry.

Thank you.

Health Information Services(MRO)
Khoo Teck Puat Hospital

OFFICIAL RECEIPT

GST REG NO.: 200717564-H

Receipt No. : MRS-76257

Date : 27 Aug 2020

ORIGINAL

SERVICE DESCRIPTION	AMOUNT (\$\$)
SPECIALIST MEDICAL REPORT ARUNKUMAR RAMAMURTHY S8260203H	 180.00
Your Ref : RA.516307.D Our Ref : SR09 2020-5639-0 Payment : CHEQUE DBS 004394	

7% GST is included in the amount charged.

Note: Administrative charges of 1/3 of the cost of medical report will be imposed if a cancellation request is made while the medical report is being processed.

For enquiries, please contact Jayne Cheong Xiu Wen
Tel No: 6602 2477/6602 2477/ Khoo Teck Puat Hospital

MEMORANDUM

From: Tan, Nicole Shu Yen

To: OPS

Date: 07-Aug-2020

ARUNKUMAR RAMAMURTHY (S8260203H) / Case: 5719403614B

38y (18-Jun-1982) / Male

Subject: Dressing change

Dear colleague,

Thank you for seeing this patient.

Mr Arunkumar was admitted to KTPH for:

1) L radial shaft #

- S/p Surgical fixation of radial shaft fracture (6/8/20)

We would like to seek your assistance in dressing change 2x/week + PRN.

STO will be done on POD14 at KTPH Ortho Clinic.

Thank you,

Tan Shu Yen Nicole

KTPH Orthopaedics HO

On behalf of Mr Allan Ng

Best Regards,



Dr. Tan, Nicole Shu Yen (P1664E)

Patient Details

Gender	: Male	DOB	: 18/06/1982 (38 years)
Race	: Indian	Citizenship	: Indian
Language	: English	Admitted	: 27/07/2020 10:59

Consult Start : 27/07/2020 11:12

Consult End : 27/07/2020 17:05

Disposition

Discharge

Referrals

Patient referred to

- KTPH SOC/Orthopaedics/Orthopaedics (Fracture) - TCU 29/7/20 (<= 5 days)

Diagnosis

Primary Diagnosis : Galeazzi's fracture of radius

Medication

Admin Time Medication Name

27/07/2020

cefalexin - CAPSULE DOSE: 500 mg - TDS - PO/Tube

orphenadrine 35 mg + paracetamol 450 mg -- ANAREX - TABLET DOSE: 2 tablet(s) - TDS - PO/Tube

Medical Certification

Certificate Type: MEDICAL CERTIFICATE

Certificate No.: KH20201843429

Type of Medical Leave granted : Hospitalization Leave

The above named attended examination / sought treatment from 26-Jul-2020 21:20 to 27-Jul-2020 17:02.

The above named is unfit for duty for a period of 4 day(s), from 26-Jul-2020 to 29-Jul-2020 inclusive.

Inpatient Discharge Summary (Patient Copy)

Patient Details

Name: ARUNKUMAR RAMAMURTHY

Address: [REDACTED]
[REDACTED]
[REDACTED]

DOB (Age): 18-Jun-1982 (38y)

NRIC: S8260203H

Race: Indian

Gender: Male

Admission Details

Admit Date: 06-Aug-20 07:09

Patient Type: Inpatient

Ward: KTPH Ward B106

Attending Dr: Ng, Shao Hui Allan

Specialty: Ortho / Gen Ortho

Case No: 5719403614B

Class: CP

Bed No: 23

MCR No: 17147F

Discharge Details

Plan Discharge Date/Time: 08-Aug-20 12:00

Actual Discharge Date/Time:

Discharge Disposition: Home

Drug Allergies

No known allergies reported from CMIS as of 06-Aug-2020 11:30

Diagnosis

Primary Diagnosis: Closed fracture of the radial shaft

Surgical Procedures

Procedure	Date
1 Anus, Perineal Abscess, Saucerisation/Drainage;	08-Apr-20
2 Wrist, Distal radius fracture, Open Reduction and Internal Fixation (ORIF) (simple open reduction and pinning);	06-Aug-20

Completed by Tan, Nicole Shu Yen (MCR: P1664E) on 07-Aug-20 15:09

Page 1

This is a computer-generated report. Please refer to your attendant for any clarification. Valid as of: 08-Aug-20 08:41